
Research Submission

CME

Treatment of Headaches in the ED With Lower Cervical Intramuscular Bupivacaine Injections: A 1-Year Retrospective Review of 417 Patients

Larry B. Mellick, MD; S. Timothy McIlrath, MD; Gary A. Mellick, DO

Objective.—The primary objective of this retrospective chart review is to describe 1 year's experience of an academic emergency department (ED) in treating a wide spectrum of headache classifications with intramuscular injections of 0.5% bupivacaine bilateral to the spinous process of the lower cervical vertebrae.

Background.—Headache is a common reason that patients present to an ED. While there are a number of effective therapeutic interventions available for the management of headache pain, there clearly remains a need for other treatment options. The intramuscular injection of 1.5 mL of 0.5% bupivacaine bilateral to the sixth or seventh cervical vertebrae has been used to treat headache pain in our facility since July 2002. The clinical setting for the study was an academic ED with an annual volume of over 75,000 patients.

Methods.—We performed a retrospective review of over 2805 ED patients with the discharge diagnosis of headache and over 771 patients who were coded as having had an anesthetic injection between June 30, 2003 and July 1, 2004. All adult patients who had undergone paraspinous intramuscular injection with bupivacaine for the treatment of their headache were gleaned from these 2 larger databases and were included in this retrospective chart review. A systematic review of the medical records was accomplished for these patients.

Results.—Lower cervical paraspinous intramuscular injections with bupivacaine were performed in 417 patients. Complete headache relief occurred in 271 (65.1%) and partial headache relief in 85 patients (20.4%). No significant relief was reported in 57 patients (13.7%) and headache worsening was described in 4 patients (1%). Overall a therapeutic response was reported in 356 of 417 patients (85.4%). Headache relief was typically rapid with many patients reporting complete headache relief in 5 to 10 minutes. Associated signs and symptoms such as nausea, vomiting, photophobia, phonophobia, and allodynia were also commonly relieved.

Conclusion.—Our observations suggest that the intramuscular injection of small amounts of 0.5% bupivacaine bilateral to the sixth or seventh cervical spinous process appears to be an effective therapeutic intervention for the treatment of headache pain in the outpatient setting.

Key words: allodynia, bupivacaine, cervical, headache, injection, intramuscular, migraine, pain, paraspinous, trigeminocervical

(*Headache* 2006;46:1441-1449)

For CME, visit <http://www.headachejournal.org>

From The Department of Emergency Medicine, Medical College of Georgia, Augusta, GA (Drs. Mellick and McIlrath); and Department of Neurology, Ashtabula County Medical Center, Ashtabula, OH (Dr. Mellick).

Address all correspondence to Dr. Larry B. Mellick, Department of Emergency Medicine, Medical College of Georgia, Augusta, GA.

Accepted for publication May 22, 2006.

Headache is a common chief complaint of patients who present to an emergency department (ED).¹ Many patients access the ED as a last resort after other therapeutic resources and interventions have failed to provide headache relief. The therapeutic interventions currently used in the ED setting often involve medications that require the placement of intravenous lines, have side effects such as cognitive impairment, extrapyramidal reactions, or may enable opiate dependency.²⁻⁴

It was first recognized in 1996 and initially reported in 2003 that bilateral lower cervical paraspinal intramuscular injections with bupivacaine appear to consistently relieve a spectrum of International Headache Society (IHS) classification headaches as well as orofacial pain.^{5,6} In July 2002 the procedure was introduced into our ED practice as a therapeutic option for headache pain. Subsequent clinical experience with this procedure suggested that a majority of ED patients with headache pain experienced a therapeutic response and typically reported relief of associated signs and symptoms including allodynia.⁷

In this paper, we describe a large retrospective case series of all headache patients treated during a 1-year period in an academic ED with bilateral lower cervical paraspinal injections with bupivacaine. This retrospective review was approved by the Medical College of Georgia human assurance committee.

METHODS

All patients 18 years of age or older who presented to the ED between June 30, 2003 and July 1, 2004, had a diagnosis of headache and underwent treatment with intramuscular injections of bupivacaine to the lower cervical paraspinal muscles were included in this study. The patients were obtained by meticulous review of 2 databases. A database of 2805 patients who had a discharge diagnosis of headache were reviewed for patients who had been treated with bupivacaine injections as was a second database of 771 patients who were coded as having had an anesthetic injection. Two research assistants reviewed every chart to determine whether or not the procedure had been performed during treatment for headache pain.

A total of 3 chart reviewers participated in data extraction. Data extraction rules were developed and

Table 1.—Therapeutic Response Definitions

| |
|--|
| I. Headache relief |
| A. Complete headache resolution documented (0/10 numerical descriptor scale, "Headache Resolved," "Headache Relieved," and "Headache Gone") |
| B. Headache relief documented (1-2/10 numerical descriptor scale) and no rescue medications required prior to discharge |
| C. Headache relief reported by patient ("feeling better," "improvement," and "good relief") and no rescue medications required prior to discharge |
| II. Partial headache relief |
| A. Reduction in pain documented by numerical descriptor scale and headache pain not reduced below 3/10 following treatment (with or without rescue medications administration prior to discharge) |
| B. Reduction in headache topography documented, but an area of residual headache reported and residual pain not below 3/10 on numerical descriptor scale documented (with or without rescue medications administration prior to discharge) |
| C. Reduction in headache topography and/or clinical improvement documented, but rescue medications required prior to discharge |
| III. No headache relief |
| A. Patient relates no significant headache relief with bupivacaine injection |
| B. No improvement documented in record and rescue medications required |
| IV. Headache pain worsened |
| A. Headache pain reported as intensified or worsened following injection |

served as the foundation for data extraction training. Definitions of headache relief, partial headache relief, and no significant relief were also established. (See Table 1.) A data extraction form was developed using Microsoft Office Excel. An initial testing of inter-rater reliability (IRR) was performed using approximately 20 patient charts. A second testing of IRR was performed following completion of data extraction.

Compliance with Health Insurance Portability and Accountability Act (HIPAA) regulations included password protected databases, obscuring of patient identifying information and locked storage with eventual destruction of chart copies used in the review.

The lower cervical injection procedure is accomplished using the following technique. After preparation of a sterile field by swabbing with an antiseptic solution over the lower cervical and upper thoracic dorsal spine, 1.5 mL of 0.5% bupivacaine HCl is

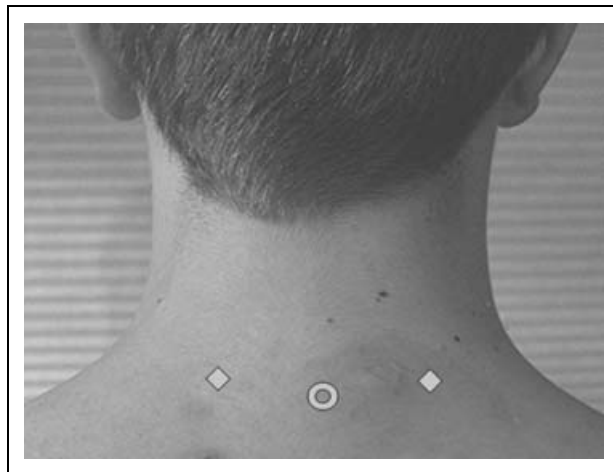


Fig 1.—The lower cervical injections are performed in the paraspinous muscles bilateral to the C6 or C7 spinous process. The injections are performed at a distance of approximately 2 to 3 cm from the spinous process.

injected into each location using a 1.5-inch 25-gauge needle. The needle is inserted 1 to 1.5 inches into the paraspinous musculature 2 to 3 cm bilateral to the spinous process of the sixth or seventh cervical vertebrae. (See Figs. 1 and 2.) The bupivacaine is injected slowly to minimize patient discomfort. The selected volume of 1.5 mL of bupivacaine is based on physician preference and the entire amount is completely deposited in a single injection location. As with any injection procedure careful identification of anatomi-

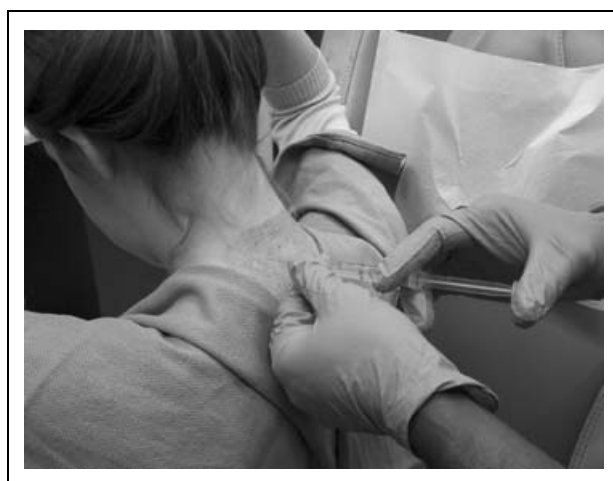

Fig 2.—A 1.5-inch, 25-gauge needle attached to 3 mL syringe filled with 0.5% bupivacaine is placed into paraspinous muscle at an angle parallel to the examination table.

cal landmarks, aspiration before injection and appropriate precautions are taken to manage potential vasodepressor syncope. Since the therapeutic response to the injection is typically unambiguous, alternative headache therapies are generally initiated within 20 to 30 minutes if the patient's pain relief is reported as inadequate or incomplete.

RESULTS

IRR testing of the 3 physicians who performed data extraction was completed twice during the study period. IRR testing was performed before formal chart review began and again at the completion of the study. The software used was STATA version 9.0 and the Kappa routine for multiple raters was used for the calculations. For each dimension, Cohen's Kappa was calculated for the 3 raters for each outcome and overall outcomes combined. Eight dimensions were tested during the initial IRR testing and 7 were evaluated during the second session. The initial IRR testing demonstrated an averaged Kappa of .7215 with the lowest Kappa being .4450 and the highest 1.0000. The averaged Kappa of the final IRR testing was .8267. The lowest Kappa score of the final IRR testing was .6227 and the highest was .9371.

Four hundred twenty-five patients 18 years of age or older underwent bilateral lower cervical paraspinous intramuscular injections with 0.5% bupivacaine as part of their headache pain management. Eight patients were excluded because of incomplete documentation of essential information. The charts of 417 patient visits were available for review. A total of 27 different attending physicians or physician assistants were documented as either performing or supervising the procedure. Headache relief following the injection was reported in 271 patients (65.1%) while 85 patients (20.4%) experienced partial relief. Fifty-seven patients (13.7%) experienced no relief and 4 patients (1%) reported worsening of their headache. Overall, a therapeutic response to the bupivacaine injections was reported in 356 patients (85.4%). (See Table 2.)

The first author was the attending physician of record for 197 or 47.2% of the injections. Headache relief was documented in 142 or 72.1% of this cohort of patients. When the relief and partial relief categories (40 patients) are combined, 92.4% of the first author's

Table 2.—Total Number of Patients and Percentages for Each Headache Relief Category

| Definition | Patient Numbers | Percent |
|----------------------------|-----------------|---------|
| Headache relief | 271 | 65.1 |
| Partial headache relief | 85 | 20.4 |
| No headache relief | 57 | 13.7 |
| Headache worsened | 4 | 1.0 |
| Total treated | 417 | 100 |
| Total therapeutic response | 356 | 85.4 |

patients demonstrated headache improvement. Other attending physicians and a physician assistant who performed the procedure independently and relatively frequently demonstrated similar results. The physician assistant treated 28 patients during the study period and had 24 patients (85.7%) who experienced headache relief and when combined with those who had a partial response (as defined in Table 1), 89.3% of the physician assistant's patients reported a therapeutic response. The 3 physicians who treated 26, 22, and 18 patients during the study period had headache relief in 61.5%, 59.1% and 83.3% of their patients, respectively. A therapeutic response (relief or partial relief) was documented in 80.7%, 90.9%, and 94.4% of their patients.

Supplemental bupivacaine injections were performed on 37 patients. These injections were typically performed on patients with an incomplete and often unilateral therapeutic response to the first set of injections. Twenty-two patients or 59.5% of the 37 patients who received a supplemental injection (usually unilateral) experienced headache relief. The first author was the attending of record for 27 of the 37 patients receiving a supplemental injection.

The reported side effects of the injection were few and included muscle soreness at the injection site, transient weakness of posterior neck muscles, relief of associated neck pain, and brightening of vision.

COMMENTS

The severity and therapeutic complexity of headache complaints presenting to an ED may be potentially greater than other clinical settings.⁸ Many patients presenting to the ED with headaches have failed

to respond to other standard therapies or the headache severity and duration has become intolerable.⁸ Central sensitization and allodynia develop over time;⁹⁻¹¹ and at least for the migraine-specific class of drugs, the triptans, it has been shown that treatment failures are more likely when treatment is started in the late headache phase.¹²⁻¹⁴

The headache relief observed with the lower cervical bilateral paraspinous bupivacaine injection appears similar to other treatment modalities studied in the ED setting. In one ED study comparing intravenous prochlorperazine against intravenous metoclopramide and placebo clinical success occurred more commonly after treatment with prochlorperazine (82%) than after metoclopramide (46%) or placebo (29%).¹⁵ The metoclopramide and placebo scores reportedly did not differ statistically. Clinically important successful treatment was defined in this report as achievement of patient satisfaction and either a decrease of 50% or more in the 30-minute pain score (compared with the initial score) or an absolute pain score of 2.5 cm or less using a 10-cm nonhatched visual analog scale. A study by Jones et al reported that 60 minutes after intravenous injection 74% (31/42) of those who received prochlorperazine had complete relief and 14% (6/42) of the patients had partial relief. Overall, there was complete or partial relief of pain in 88% (37/42) of the drug group and in 45% (18/40) of the placebo group.¹⁶ Ginder et al studied intravenous magnesium and intravenous prochlorperazine.¹⁷ This study enrolled 36 similar patients. Complete or partial pain relief was reported in 90% of the prochlorperazine group and 56% of the MgSO₄ group. None of the prochlorperazine patients required additional medication during the study period. A study by Tek et al attempted to determine the effectiveness of IV metoclopramide against placebo. Analysis of the data showed that 67% of the metoclopramide group obtained sufficient relief to allow discharge from the ED without further treatment compared with 19% for the placebo group.¹⁸ An ED headache study by Friedman et al compared 20 mg of IV metoclopramide (given up to 4 times over 2 hours as needed for persistent headache) with 6 mg of subcutaneous (SC) sumatriptan. On an 11-point pain scale the change in pain intensity by 2 hours for the metoclopramide group was 7.2 compared

with 6.3 for the sumatriptan group. At 2 hours, pain-free rates were 59% in the metoclopramide arm and 35% in the sumatriptan arm.¹⁹ A meta-analysis of randomized controlled trials summarized that even though metoclopramide was better than placebo, 3 studies suggested that it may provide less relief from pain and nausea than other phenothiazine antiemetics (prochlorperazine and chlorpromazine).²⁰ In another study comparing the efficacy of SC sumatriptan injection versus placebo for acute migraine headaches, ED patients were randomized to receive 6 mg sumatriptan SC or placebo. One hundred thirty-six patients were enrolled in this study. Seventy percent of patients in the sumatriptan group versus 35% in the placebo group reported mild or no pain at discharge.²¹ A systematic review of the literature for dihydroergotamine (DHE) in the management of acute migraine headache concluded that in 3 studies results failed to demonstrate a significant benefit of DHE over sumatriptan and phenothiazines. In 8 combination treatment studies, DHE administered with an antiemetic was reported to be as effective as or more effective than meperidine (MEP), valproate, or ketorolac across all pain, nausea, and relapse outcomes.²² DHE was compared with 1.5 mg/kg of MEP in a prospective, double-blind randomized study by Carleton et al in 1998. Reduction of headache pain as measured on a 100-mm visual analog scale was 41 ± 33 mm (53.5% reduction) for the DHE group, and 45 ± 30 mm (55.7% reduction) for the MEP group at 60 minutes after treatment. DHE and MEP were considered comparable therapies for acute migraine.²³ In general, there is consensus that MEP is less effective and opioids less desirable than other available agents.^{2,24}

It is unclear to the authors if the deep intramuscular injection used in this series should be considered a nerve block of the lower cervical dorsal roots or if its effect is mediated through the sensory dermatome of that level. It is also not clear if it shares a similar mechanism of action to other reported blocks. Nevertheless, headaches have been treated with peripheral nerve blocks for decades and²⁵ greater occipital nerve blocks, facet blocks, third occipital nerve blocks, sympathetic nerve blockade for cluster headaches and the lower cervical injection described in this paper all place anesthetic deep into tissues on the back of the

neck. And, in multiple small case series evidence of headache relief greater than what can be attributed to a placebo effect alone have been reported.²⁶⁻³¹ There may even be shared antinociceptive mechanisms with botulinum toxin, type A. Investigation of the antinociceptive effects of botulinum toxin, type A (BoNT/A) indicates that BoNT/A inhibits peripheral sensitization thereby resulting in a reduction of central sensitization.³² While the technique and evidence of anatomical specificity for other blocks is convincing, perhaps it is possible that all blocks and this lower cervical intramuscular injection share a common mechanism of headache relief.

The mechanism of headache relief following lower cervical paraspinous bupivacaine injections is unknown. Relief of headache pain and associated signs and symptoms including allodynia suggest that the sensitized trigeminocervical complex has been calmed. Many other medications that effectively relieve headaches appear to work through an effect on the trigeminocervical complex and cell activity of second order neurons is reduced.³³⁻³⁶ Convergence of cervical and trigeminal afferents to the brainstem has been well established with different lines of evidence.³⁷⁻⁴¹ In addition, descending inhibitory projections from brainstem structures such as the periaqueductal gray (PAG), nucleus raphe magnus, and the rostroventral medulla synapse the trigeminocervical complex and have a profound antinociceptive effect.^{41,42} Central antinociception pathways may also play a role in the observed pain control.

There are other reports of anesthetic blocks to the neck and head that have similarities to this retrospective review. Brofeldt and Panacek reported a case series of patients responsive to pericranial injection therapy for the treatment of headaches resistant to standard pharmacologic therapy.⁴³ Their injections focused on the suboccipital and anterior temporal areas. Focal areas where palpation augmented the headache symptoms were selected as injection locations. Their anesthetic was injected in a fanning motion through the areas of maximal tenderness. Brofeldt and Panacek's local anesthetic injections also resolved headache pain, photophobia, blurred vision, nausea, and vomiting. The authors hypothesized that the resolution of symptoms was due to interrupting

nociceptive signals originating in the temporal and suboccipital areas. Hecht et al used occipital nerve blocks to relieve postconcussive headaches in a small series of patients.⁴⁴ Caputi et al reported positive results with greater occipital nerve and supraorbital nerve blocks in patients with migraine headaches.⁴⁵ These authors postulated that presumed foci of nociceptor discharges were blocked and normal central neuron sensitivity was reestablished. Another study by Ashkenazi and Young reported 17 of 19 patients (89.5%) whose headaches responded within 20 minutes to greater occipital nerve blocks (GONB) and trigger point injections. Allodynia reduction was also measured and documented. The authors attributed the headache relief to the GONB effect on sensitized neurons in the trigeminocervical complex.⁴⁶

LIMITATIONS

This study has a number of potential limitations. The nonvalidated criteria for documented pain relief were developed because a unique tool was needed to define pain relief in this retrospective review (Table 1). We attempted to accurately define pain relief consistent with clinical experience and match as closely as possible pain relief definitions found in prospective studies. The numerical descriptor scale was a predominant component of our pain relief documentation and has been previously validated in the ED setting.⁴⁷

In contrast to many prospective pharmaceutical studies that documented pain relief at 2 hours, the clinical practice in our ED was to initiate rescue therapies if the injection had not sufficiently relieved the patient's headache within 20 to 30 minutes. By 2 hours following therapy, the patients in this study were either discharged or had been treated with 1 or more rescue medications. Consequently, the actual number of patients experiencing relief following the procedure may have been underestimated.

A percentage of the reported headache relief responses were undoubtedly related to a placebo effect. As a retrospective review, the placebo effect was not measured in this study. While the recognized placebo effect of headache pain management is significant, the observed response is much greater than placebo effects reported in a headache placebo study. A meta-analysis of 22 trials was performed to determine the

comparative placebo effect of SC versus oral administration in the treatment of migraine.⁴⁸ For the oral regimen, 25.7% of the participants reported no or mild headache severity after 2 hours compared to 32.4% of those receiving SC placebo.⁴⁸ Similar placebo effects are reported in multiple pharmaceutical trials. In this review, 65.1% of our patients experienced headache relief and another 20.4% experienced partial relief.

Because the setting of the study was a teaching hospital ED, many of the lower cervical injections were performed by rotating physicians recently trained in the procedure. It is probable that procedural skill varied even though individual training was provided to all healthcare providers who performed the injection. Consequently, treatment failures or partial therapeutic responses may have occurred secondary to the faulty technique of novice operators.

It is also possible that one physician, the first author, being responsible for 47.2% of the procedures, might have introduced bias into the study. The potential for influencing outcomes through patient selection, suggestion, and documentation does exist. Nevertheless, when compared with others who relatively more frequently and independently performed the procedure, outcomes appear similar.

In this retrospective review of ED charts, the quality of data collected was dependent on completeness of chart documentation. Inadequate or missing documentation potentially influenced our assessments of therapeutic outcome.

Finally, a spectrum of primary and secondary headaches (migraine, tension-type, chronic, viral meningitis, postdural puncture, head trauma, influenza, and nitroglycerin associated) was treated. No attempt was made in this study to differentiate the type of headache or correlate an International Headache Society (IHS) classification with the documented therapeutic response. In that IHS classification is possibly more difficult in the ED setting,^{49,50} and chart documentation consistently lacked necessary data elements, IHS classification was not accomplished. It is possible, however, that the results might vary if this intervention was studied for a single type of headache. In their 1998 review article, Newman and Lipton⁸ reported that migraine and tension headaches accounted for 25% and 55% of ED patient headaches, systemic

illness accounted for another 33% to 39% and 1% to 16% of ED headaches were secondary to serious neurologic conditions.

CONCLUSION

In conclusion, this is the first report of a large number of patients whose headaches were relieved with bilateral lower cervical paraspinal injections with bupivacaine. The headache relief is typically accompanied by interruption of associated signs and symptoms including allodynia. While the therapeutic mechanism is unknown, it is possible that a sensitized trigeminocervical complex is somehow quieted and/or descending inhibitory antinociception by the PAG and related structures contributes to the relief. Our observations suggest that the intramuscular injection of small amounts of 0.5% bupivacaine bilateral to the sixth or seventh cervical spinous process appears to be a safe and effective therapeutic intervention for the treatment of headache pain caused by a spectrum of etiologies presenting in the ED setting.

Acknowledgment: The authors would like to thank Henry Millwood, MD for his assistance with data collection and Jim Wilde, MD, for his critical review of the manuscript. The contributions of our 2 research assistants, Davis Mellick and Selvin Jeremiadoss, are also greatly appreciated.

Conflict of Interest: None

REFERENCES

1. McCaig LF, Burt CS. National hospital ambulatory medical care survey: 2003 emergency department summary. *Adv Data*. 2005;358:1-40.
2. Vinson DR. Treatment patterns of isolated benign headache in US emergency departments. *Ann Emerg Med*. 2002;39:215-222.
3. Vinson DR, Hurtado TR, Vandenberg JT, Banwart L. Variations among emergency departments in the treatment of benign headache. *Ann Emerg Med*. 2003;41:90-97.
4. Colman I, Rothney A, Wright SC, Zilkalns B, Rowe BH. Use of narcotic analgesics in the emergency department treatment of migraine headache. *Neurology*. 2004;62:1695-1700.
5. Mellick GA, Mellick LB. Lower cervical injections for headache relief. Letter. *Headache*. 2001;41:992-994.
6. Mellick GA, Mellick LB. Regional head and face pain relief following lower cervical intramuscular anesthetic injection. *Headache*. 2003;43:1111-1113.
7. Mellick LB, Mellick GA. Treatment of primary headache in the emergency department. Letter. *Headache*. 2004;44:840-841.
8. Newman LC, Lipton RB. Emergency department evaluation of headache. *Neurol Clin*. 1998;16:285-303. Review.
9. Malick A, Burstein R. Peripheral and central sensitization during migraine. *Funct Neurol*. 2000;15(suppl 3):28-35. Review.
10. Burstein R, Yarnitsky D, Goor-Aryeh I, Ransil BJ, Bajwa ZH. An association between migraine and cutaneous allodynia. *Ann Neurol*. 2000;47:614-624.
11. Burstein R, Cutrer MF, Yarnitsky D. The development of cutaneous allodynia during a migraine attack: Clinical evidence for the sequential recruitment of spinal and supraspinal nociceptive neurons in migraine. *Brain*. 2000;123(Pt 8):1703-1709.
12. Burstein R, Jakubowski M. Analgesic triptan action in an animal model of intracranial pain: A race against the development of central sensitization. *Ann Neurol*. 2004;55:27-36.
13. Burstein R, Collins B, Jakubowski M. Defeating migraine pain with triptans: A race against the development of cutaneous allodynia. *Ann Neurol*. 2004;55:19-26.
14. Cady RK, Sheftell F, Lipton RB, et al. Effect of early intervention with sumatriptan on migraine pain: Retrospective analyses of data from three clinical trials. *Clin Ther*. 2000;22:1035-1048.
15. Coppola M, Yealy DM, Leibold RA. Randomized, placebo-controlled evaluation of prochlorperazine versus metoclopramide for emergency department treatment of migraine headache. *Ann Emerg Med*. 1995;26:541-546.
16. Jones J, Sklar D, Dougherty J, White W. Randomized double-blind trial of intravenous prochlorperazine for the treatment of acute headache. *JAMA*. 1989;261:1174-1176.
17. Ginder S, Oatman B, Pollack M. A prospective study of i.v. magnesium and i.v. prochlorperazine in the treatment of headaches. *J Emerg Med*. 2000;18:311-315.

18. Tek DS, McClellan DS, Olshaker JS, Allen CL, Arthur DC. A prospective, double-blind study of metoclopramide hydrochloride for the control of migraine in the emergency department. *Ann Emerg Med.* 1990;19:1083-1087.
19. Friedman BW, Corbo J, Lipton RB, et al. A trial of metoclopramide vs sumatriptan for the emergency department treatment of migraines. *Neurology.* 2005;64:463-468.
20. Colman I, Brown MD, Innes GD, Grafstein E, Roberts TE, Rowe BH. Parenteral metoclopramide for acute migraine: Meta-analysis of randomised controlled trials. *BMJ.* 2004;329:1369-1373.
21. Akpunonu BE, Mutgi AB, Lee L, Khuder S, Federman DJ, Roberts C. Subcutaneous sumatriptan for treatment of acute migraine in patients admitted to the emergency department: A multicenter study. *Ann Emerg Med.* 1995;25:464-469.
22. Colman I, Brown MD, Innes GD, Grafstein E, Roberts TE, Rowe BH. Parenteral dihydroergotamine for acute migraine headache: A systematic review of the literature. *Ann Emerg Med.* 2005;45:393-401. Review.
23. Carleton SC, Shesser RF, Pietrzak MP, et al. Double-blind, multicenter trial to compare the efficacy of intramuscular dihydroergotamine plus hydroxyzine versus intramuscular meperidine plus hydroxyzine for the emergency department treatment of acute migraine headache. *Ann Emerg Med.* 1998;32:129-138.
24. Snow V, Weiss K, Wall EM, Mottur-Pilson C. American Academy of Family Physicians; American College of Physicians-American Society of Internal Medicine. Pharmacologic management of acute attacks of migraine and prevention of migraine headache. *Ann Intern Med.* 2002;137:840-849.
25. Ashkenazi A, Silberstein SD. Headache management for the pain specialist. *Reg Anesth Pain Med.* 2004;29:462-475. Review.
26. Peres MFP, Stiles MA, Siow HC, Rozen TD, Young WB, Silberstein SD. Greater occipital nerve blockade for cluster headache. *Cephalalgia.* 2002;22:520-522.
27. Bogduk N, Marsland A. On the concept of third occipital headache. *J Neurol Neurosurg Psychiatry.* 1986;49:775-780.
28. Lord SM, Barnsley L, Wallis BJ, Bogduk N. Third occipital nerve headache: A prevalence study. *J Neurol Neurosurg Psychiatry.* 1994;57:1187-1190.
29. Aprill C, Axinn MJ, Bogduk N. Occipital headaches stemming from the lateral atlanto-axial (C1-2) joint. *Cephalalgia.* 2002;22:15-22.
30. Anthony M. Cervicogenic headache: Prevalence and response to local steroid therapy. *Clin Exp Rheumatol.* 2000;8(2 suppl 19):S59-S64.
31. Albertyn J, Barry R, Odendaal CL. Cluster headache and the sympathetic nerve. *Headache.* 2004;44:183-185.
32. Aoki KR. Evidence for antinociceptive activity of botulinum toxin type A in pain management. *Headache.* 2003;43(suppl 1):S9-S15.
33. Hoskin KL, Kaube H, Goadsby PJ. Sumatriptan can inhibit trigeminal afferents by an exclusively neural mechanism. *Brain.* 1996;119(Pt 5):1419-1428.
34. Kaube H, Hoskin KL, Goadsby PJ. Intravenous acetylsalicylic acid inhibits central trigeminal neurons in the dorsal horn of the upper cervical spinal cord in the cat. *Headache.* 1993;33:541-544.
35. Hoskin KL, Kaube H, Goadsby PJ. Central activation of the trigeminovascular pathway in the cat is inhibited by dihydroergotamine. A c-Fos and electrophysiological study. *Brain.* 1996;119(Pt 1):249-256.
36. Kaube H, Katsarava Z, Przywara S, Drepper J, Ellrich J, Diener HC. Acute migraine headache: Possible sensitization of neurons in the spinal trigeminal nucleus? *Neurology.* 2002;58:1234-1238.
37. Abrahams VC, Anstee G, Richmond FJ, Rose PK. Neck muscle and trigeminal input to the upper cervical cord and lower medulla of the cat. *Can J Physiol Pharmacol.* 1979;57:642-651.
38. Piovesan EJ, Kowacs PA, Tatsui CE, Lange MC, Ribas LC, Werneck LC. Referred pain after painful stimulation of the greater occipital nerve in humans: Evidence of convergence of cervical afferences on trigeminal nuclei. *Cephalalgia.* 2001;21:107-109.
39. Bartsch T, Goadsby PJ. Stimulation of the greater occipital nerve induces increased central excitability of dural afferent input. *Brain.* 2002;125:1496-1509.
40. Bartsch T, Goadsby PJ. Increased responses in trigeminocervical nociceptive neurons to cervical input after stimulation of the dura mater. *Brain.* 2003;126:1801-1813.
41. Bartsch T, Goadsby PJ. The trigeminocervical complex and migraine: Current concepts and synthesis. *Curr Pain Headache Rep.* 2003;7:371-376. Review.

42. Mason P. Deconstructing endogenous pain modulations. *J Neurophysiol.* 2005;94:1659-1663. Review.
43. Brofeldt BT, Panacek EA. Pericranial injection of local anesthetics for the management of resistant headaches. *Acad Emerg Med.* 1998;5:1224-1229.
44. Hecht JS. Occipital nerve blocks in postconcussive headaches: A retrospective review and report of ten patients. *J Head Trauma Rehabil.* 2004;19:58-71.
45. Caputi CA, Vincenzo F. Therapeutic blockade of greater occipital and supraorbital nerves in migraine patients. *Headache.* 1997;37:174-179.
46. Ashkenazi A, Young W. The effects of greater occipital nerve block and trigger point injection on brush allodynia and pain in migraine. *Headache.* 2005;45:350-354.
47. Bijur PE, Latimer CT, Gallagher EJ. Validation of a verbally administered numerical rating scale of acute pain for use in the emergency department. *Acad Emerg Med.* 2003;10:390-392.
48. de Craen AJ, Tijssen JG, de Gans J, Kleijnen J. Placebo effect in the acute treatment of migraine: Subcutaneous placebos are better than oral placebos. *J Neurol.* 2000;247:183-188.
49. Fiesseler FW, Kec R, Mandell M, et al. Do ED patients with migraine headaches meet internationally accepted criteria? *Am J Emerg Med.* 2002;20:618-623.
50. Fiesseler FW, Riggs RL, Holubek W, Eskin B, Richman PB. Canadian Headache Society criteria for the diagnosis of acute migraine headache in the ED—do our patients meet these criteria? *Am J Emerg Med.* 2005;23:149-154.